



**Cathy Woodlands** BSc(Hons) VNPA  
GradDipVN RVN

Cathy graduated from Bristol University in 2009 after studying the Veterinary Nursing and Practice Administration degree. She then completed the RVC Diploma in Professional and Clinical Veterinary Nursing. Cathy works at Bath Veterinary Referrals as deputy head referral nurse and is on the nurse committee for Independent Vet Care. Email: [cathy.woodlands@bathvetreferrals.co.uk](mailto:cathy.woodlands@bathvetreferrals.co.uk)

# Laparoscopic spay

**Cathy Woodlands** BSc(Hons) VNPA GradDipVN RVN  
Bath Veterinary Referrals, Wellsway, Bath, BA2 5RL UK

Neutering animals is a routine procedure in veterinary practice with female dogs and cats being admitted for an ovariohysterectomy on a daily basis.

Bitches are spayed for a variety of reasons, including:

- Control of reproduction – preventing unwanted litters
- Mammary tumours – the most common type of malignant tumour in female dogs; the risk of mammary tumours increases with age and number of seasons (0.5% if spayed before the first oestrus, 8% after the first oestrus and after the second oestrus a 26% risk) (Battisti, 2012).
- Pyometras – an infection which infiltrates through the cervix (which opens during season and after pregnancy) where the uterus becomes infected and pus-filled and can be life-threatening
- Behavioural reasons – increased urination (to attract a male), nervousness during ovulation and avoidance of false pregnancy.

## Spaying

### Ovariohysterectomy versus ovariectomy

Spaying is a term used for any surgical procedure that involves removal of the ovaries and traditionally neutering of female dogs is achieved by a surgical procedure known as an ovariohysterectomy. This involves a midline incision into the abdomen removing the uterus and the ovaries. More recently, laparoscopic spays have been carried out which involve removing the ovaries alone (ovariectomy). Laparoscopy is a new technique which carries improved post-operative recovery advantages such as smaller incisions, less trauma and increased visualisation (Shariati, Bakhtiari, Khalaj, & Niasari-Naslaji, 2014).

## Laparoscopy equipment

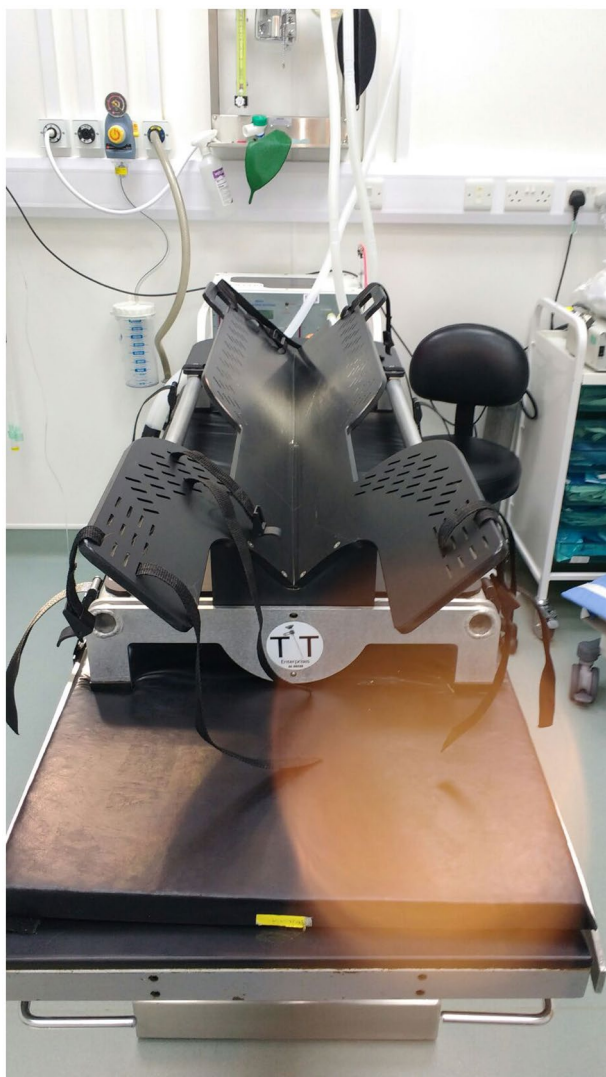
Specialist equipment is required to be able to carry out laparoscopic spays in practice. The cost of the equipment required for laparoscopy can be seen as one potential disadvantage when considering laparoscopy in practice (Culp, Mayhew, & Brown, 2009).

- Specialist table (TT endoscopic positioner) (**Figure 1**) is used to be able to position the patient and move the patient from one side to another.
- Carbon dioxide insufflator
- Trochars (5 mm or 10 mm; **Figure 2**)
- Insufflation hose
- Laparoscopy tower and screen
- Light source
- Laparoscope
- Vessel sealing device, e.g. Ligasure TM
- Babcock forceps
- Camera sheath
- Standard equipment required for surgery.

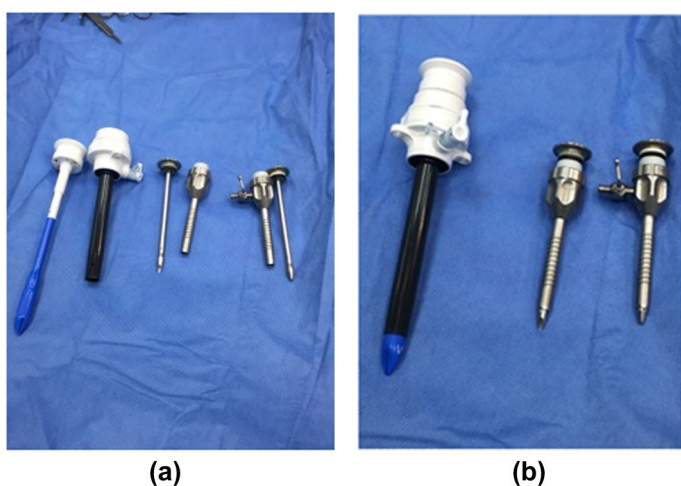
## Surgical procedure

First, the patient is anaesthetised and prepared for surgery by clipping from the mid xiphoid to the pubis. A surgical scrub is carried out using chlorhexidine and then the patient is moved into theatre and positioned on the table and secured into position to prevent movement when the table is rotated. Rotating the table improves the veterinary surgeon's visualisation of the ovaries; in smaller dogs, this can be achieved using sandbags or a small trough. In larger patients, however, there is a risk of the patient slipping out of position; therefore, the TT endoscopic positioner is used to prevent this from happening as it allows the patient to be secured to the table during rotation.

Two or three keyhole incisions are created through the skin and muscle into the abdominal cavity in which



▲ Figure 1. TT Endoscopic Positioner



▲ Figure 2. Trochars 5mm and 10mm

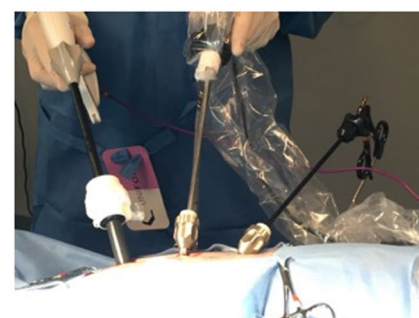
the surgeon places three trochars into the abdomen. The trochars are portals which enable the surgeon to place other surgical instruments required into the abdomen for the procedure.

An insufflation hose is connected to the carbon dioxide via an insufflation unit and one of the trochars. The carbon dioxide inflates the abdomen, allowing visualisation for the surgical procedure.

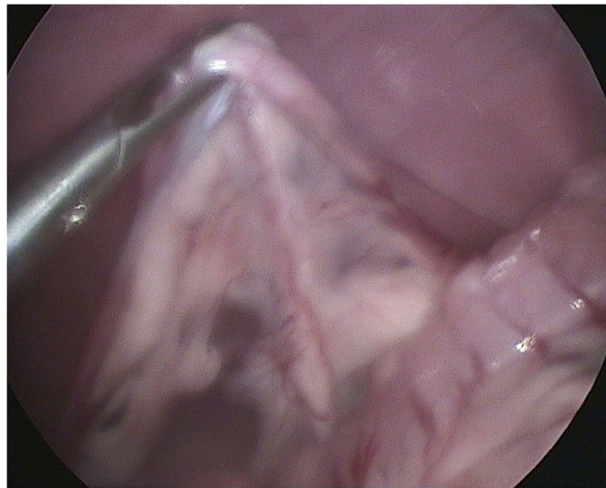
A laparoscope is inserted into one trochar and connected to the screen on the laparoscopy tower (using a camera cover to maintain sterility of the non-sterile camera cable) for the surgeon to visualise the abdomen and organs; the next trochar is used for the babcock forceps which grasp the ovarian ligament/ovary; and finally the third trochar allows placement of the Ligasure hand piece, which permanently fuses vessels using a combination of pressure and energy and cuts the tissue (Figure 3).

The surgeon locates the ovary and the ovarian suspensory ligament and grasps it using the babcock forceps; it is important not to grasp the ovary itself as this can cause seeding and ovarian remnant syndrome (Figure 4). The Ligasure is used to create haemostasis by coagulating and sealing the ovarian suspensory ligament and blood supply and then cutting the tissue using the blade within the hand piece (McCabe, 2009). The ovary is then removed via the trochar and checked to ensure it has been removed in its entirety. This is then repeated on the other ovary using the same technique. Once both ovaries have been removed the abdomen is checked for any signs of haemorrhage. Haemorrhage is one of the most common complications after an ovariohysterectomy; however, recent studies have shown that laparoscopic ovariectomies create less haemorrhage due to increased visualisation, less manipulation and better coagulation due to the use of a haemostatic system (Shariati et al., 2014). The instruments are then removed and the abdomen deflated. The muscle and skin layers are sutured using PDS and Ethilon and Marcain for analgesia (Figure 5).

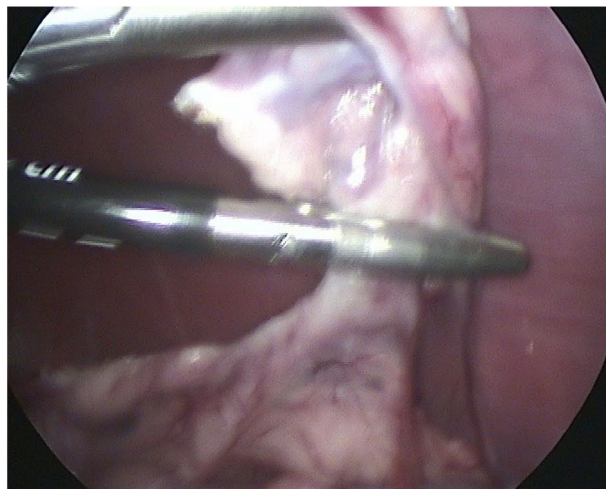
This technique is known as a three-port technique; however, there are other



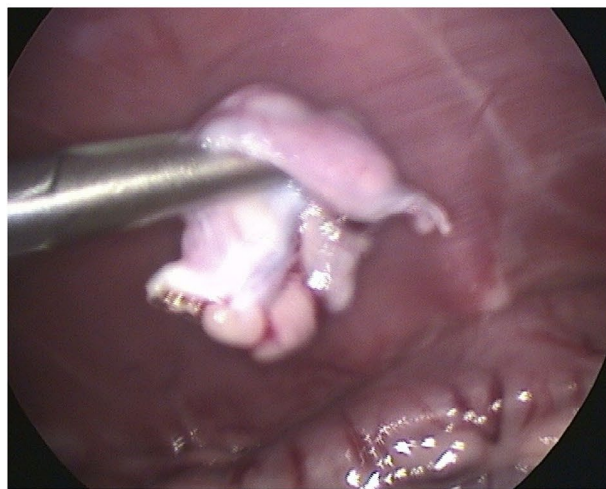▲ Figure 3. Positioning of laparoscopic instruments and trochars



(a)



(b)

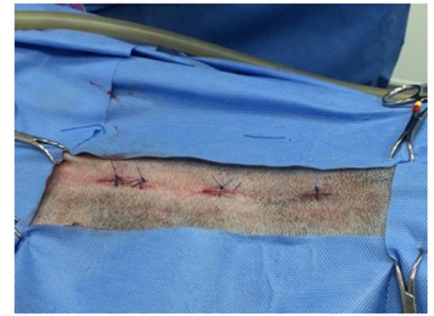

(c)

▲ **Figure 4.** Ovary and Ligasure via laparoscope

techniques which involve the use of two trochars. In order to be able to use two trochars an ovariectomy hook (**Figure 6**) is used to secure the ovary to the abdominal wall – this allows the surgeon to remove the laparoscopy forceps which

secure the ovary and replace them with the Ligasure, therefore only needing two portals. This technique requires a wider abdominal clip to allow for sterility to be maintained.



▲ **Figure 5.** Post surgical wound



▲ **Figure 6.** Ovariectomy hook

### Laparoscopic gastropexy

Laparoscopic gastropexy is a surgical procedure used to prevent gastric dilatation volvulus (GDV), which is where the stomachs bloats and twists and is a life-threatening condition. Certain breeds are predisposed to this condition and they include Great Danes, Weimeraners, Irish Setters, Dobermans and Pointers. This procedure can be carried out at the same time as the laparoscopic ovariectomy and involves suturing the stomach to the body wall so that it cannot twist or move. One study by Rivier, Furneaux, and Viguier(2011) looked at performing prophylactic gastropexy at the same time as a laparoscopic ovariectomy. They found that surgical time for this procedure by an experienced surgeon was no longer in comparison to using an open technique and none of the dogs involved in the study had any further episodes of GDV. In conclusion, this technique results in low morbidity, low risk of suture dehiscence (the right side of the stomach wall was attached to the body wall one year post-surgery) and good visibility of abdominal structures with a minimally invasive procedure.

## Benefits

Laparoscopy has become more common in human medicine due to the decrease in post-operative pain. One study by Devitt, Cox, and Hailey (2005) compared the surgical stress and pain of patients undergoing an OVH or laparoscopic ovariectomy (LapOVH) – they found that none of the LapOVH dogs required any additional pain relief after pain scores were carried out post-operatively; however, in the OVH group 9 out of 10 dogs needed additional analgesia. In conclusion they found that LapOVH caused less pain and surgical stress post-operatively than an OVH. Another study by Culp et al. (2009) found that post-operative activity between patients that had an open ovariectomy or laparoscopic ovariectomy were significantly different, with animals that had a LapOVE were more active post-operatively.

## Surgical pain

Any veterinary nurse involved in the anaesthetic for an OVH will tell you that the patient can begin to hyperventilate under the anaesthetic when the veterinary surgeon starts to pull on the suspensory ligaments. From the author's experience of anaesthetic for LapOVE this does not occur due to the minimal tension on the uterus and ovarian ligament.

## Shortened surgical time

For veterinary surgeons laparoscopic spays are a learning curve the same as any other surgical technique. In the early stages of performing this procedure this can result in increased surgical time between OVH and OVE. However, as this procedure becomes more routine in practice, surgical times are the same if not faster than an OVH. One study by Culp et al. (2009) found that the surgical times between an open ovariectomy (OOVE) and laparoscopic ovariectomy (LapOVE) resulted in the median surgical time being shorter for the OOVE; however, the LapOVE was still only 30 min. This emphasises the need for surgical experience and training when new techniques are used in practice.

There has also been some discussion into the risk of not removing the uterus during surgery, with some arguing this could potentially leave the animal at risk to uterine disease. Studies have shown that patients that have had an OVE did not develop pyometras or endometritis in a questionnaire completed by owners 6–11 years after the surgery (Findji, 2014).

## Anaesthesia and laparoscopy

When the abdomen is inflated this causes an increase in intra-abdominal pressure which affects both the respiratory and cardiovascular system. For the respiratory system the diaphragm is pushed cranially, resulting in a decreased area for lung expansion and less gaseous exchange. The carbon dioxide used to inflate the abdomen can be absorbed by the patient into the systemic circulation, resulting in hypercapnia (Miller, 2016). During laparoscopy pulse oximetry and capnography should be used to monitor for these changes and potential problems, although in my experience complications are rare. One study investigating the cardiopulmonary effects of using carbon dioxide for laparoscopy in cats found that using carbon dioxide as the insufflation gas to produce an intra-abdominal pressure of 12 mmHg in healthy animals produced minimal cardiovascular and pulmonary changes despite no ventilation support (Beazley, Cosford, & Duke-Novakovski, 2011). Nurses should bear this in mind when monitoring anaesthetics involving laparoscopy and increased intra-abdominal pressure.

## Conclusion

Laparoscopy is becoming more widely used in veterinary practice; it can be used to neuter dogs by ovariectomy as discussed and has many other uses. These include laparoscopic-assisted gastropexy, liver biopsies, cryptorchid surgery and thoracoscopy. The main disadvantages are the initial set-up cost for the equipment required and the learning curve for the veterinary surgeon. With the procedure being

less-invasive it decreases the post-operative pain and although it can take more surgical time at the beginning of the surgeon's training, this decreases with experience. For the veterinary nurse the patient preparation is similar to that of an ovariectomy in terms of the area to clip and surgical scrub. Laparoscopy is not only a learning curve for the veterinary surgeon but the veterinary nurse as well – there is a large amount of equipment to become familiar with and this can extend the time it takes in surgery to set everything up. However, once you are familiar with the equipment required and the set up for the procedure the additional time is minimal.

## References

- Battisti, A. (2012) Canine neutering when and how. *Veterinary times*. [online]. Retrieved February 15, 2016, from [www.vetsonline.com/publications/veterinary-times/archives/n-42-22/canine-neutering-when-and-how.html](http://www.vetsonline.com/publications/veterinary-times/archives/n-42-22/canine-neutering-when-and-how.html)
- Beazley, S. G., Cosford, K., & Duke-Novakovski, T. (2011). Cardiopulmonary effects of using carbon dioxide for laparoscopic surgery in cats. *Canadian Veterinary Journal*, 52(9), 973–978.
- Culp, W.T.N., Mayhew, P.D., & Brown, D.C. (2009). The effect of laparoscopic versus open ovariectomy on postsurgical activity in small dogs. *Veterinary Surgery*, 38(7), 811–817.
- Devitt, C. M., Cox, R. E., & Hailey, J. J. (2005). Duration, complications, stress and pain of open ovariectomy versus a simple method of laparoscopic-assisted ovariectomy in dogs. *Journal of the American Veterinary Medical Association*, 227(6), 921–927.
- Findji, L. (2014). Ovariectomy VS Ovariectomy. *Clinicians brief* [online]. Retrieved February 15, 2016, from [www.cliniciansbrief.com/article/ovariectomy-vs-ovariectomy](http://www.cliniciansbrief.com/article/ovariectomy-vs-ovariectomy)
- McCabe, T. (2009). How to perform a two portal laparoscopic ovariectomy. *Veterinary Medicine*, [online]. Retrieved January, 2016, from <http://veterinarymedicine.dvm360.com/how-perform-two-portal-laparoscopic-ovariectomy>
- Miller, C. (2016). Anaesthetic considerations for laparoscopic surgery in canines. *Veterinary Times*, [Online]. Retrieved February 5, 2016, from [www.vettimes.co.uk/article/anaesthetic-considerations-for-laparoscopic-surgery-in-canines/](http://www.vettimes.co.uk/article/anaesthetic-considerations-for-laparoscopic-surgery-in-canines/)
- Rivier, P., Fumeaux, R., & Viguiet, E. (2011). Combined laparoscopic ovariectomy and laparoscopic-assisted gastropexy in dogs susceptible to gastric dilatation-volvulus. *Canadian Veterinary Journal*, 52(1), 62–66.
- Shariati, E., Bakhtiari, J., Khalaj, A., & Niasari-Naslaji, A. (2014). Comparison between two portal laparoscopy and open surgery for ovariectomy in dogs. *Veterinary Research Forum*, 5(3), 219–223.

## Multiple Choice Questions

1. A laparoscopic gastropexy can be used to:

- (a) Untwist a stomach
- (b) Prevent rotation of a stomach
- (c) Remove part of the stomach
- (d) Shrink the stomach

2. The risk of mammary tumours increases with age and number of seasons. What percentage of bitches might develop mammary tumours if they are neutered between the first and second season?

- (a) 0.5%
- (b) 8%
- (c) 15%
- (d) 26%

3. This article suggests a potential complication of a laparoscopic

spay is:

- (a) Increased surgical pain
- (b) Increased surgical time
- (c) Respiratory depression
- (d) Decreased patient activity post-surgery

4. The Ligasure® device is used to:

- (a) Position and rotate the patient on the table
- (b) Regulate gas pressure in the abdomen
- (c) Seal blood vessels
- (d) Enable instruments to be passed into the abdomen

5. Laparoscopic spays are:

- (a) Removal of the ovaries and uterus

(b) Removal of the uterus only

- (c) Removal of the ovaries only
- (d) Ligation of the uterine horns

6. What gas is used to inflate the patients' abdomen during a laparoscopic spay?




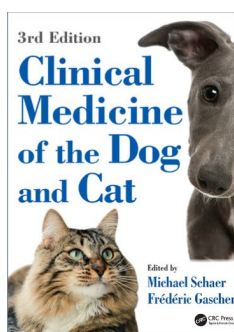

- (a) Carbon dioxide
- (b) Oxygen
- (c) Nitrous oxide
- (d) Room air

7. Trochars are used as:

- (a) Devices to position the patient on the table
- (b) Regulators of gas pressure in the abdomen
- (c) Ligation devices to seal vessels
- (d) Portals to place other surgical instruments required

For the answers to the MCQs, please go to: <http://www.bvna.org.uk/publications/veterinary-nursing-journal>

## EXCLUSIVE 20% DISCOUNT on all CRC Press books for VNJ readers



Simply visit [www.crcpress.com](http://www.crcpress.com) and enter code **VNJ17** when ordering to claim your 20% DISCOUNT, plus free shipping!

[www.crcpress.com](http://www.crcpress.com)

