



# Osteoarthritis management in an onychectomised African serval

Sophie Sparrow, RVN, BSc (Hons)

ZSL London Zoo, London

✉ [sophie.sparrow@zsl.org](mailto:sophie.sparrow@zsl.org)

Sophie graduated from Harper Adams University in 2011 with a BSc (Hons) in veterinary nursing and practice management. She has worked predominantly in zoological institutions and is now Senior Veterinary Nurse at ZSL London Zoo. She is combining her interest in conservation veterinary nursing and rehabilitation by studying for a diploma in animal physiotherapy.



**ABSTRACT** Osteoarthritis is common in older domestic and captive exotic felids and impacts their quality of life. An African serval (*Leptailurus serval*) had undergone an onychectomy (declaw) on all four paws, prior to confiscation from the pet trade. Physiological changes later in the serval's life can be attributed to this, with radiographic evidence of bony changes

at the onychectomy site of the second phalanx in the digits, with concurrent stifle osteoarthritis. Non-pharmacological interventions and pharmacological agents were used in the management of the condition.

**Keywords** osteoarthritis, African serval, onychectomy

## Introduction

Onychectomy (declawing) is the surgical amputation of the claws and distal phalanx (P3), most commonly of the front paws but can include all four paws (Ruch-Gallie et al., 2016; American Veterinary Medical Association (AVMA), 2019). In 2006, the Animal Welfare Act outlawed declawing in the UK. The law prohibits mutilation, specifically: *'interference with the sensitive tissues or bone structure of the animal, otherwise than for the purpose of its medical treatment'*. However, onychectomy is still performed in countries where it is legal, despite well-documented short-term physiological and psychological complications (Martell-Moran et al., 2018). There is currently less available research into the long-term physiological impacts and complications of onychectomy.

Osteoarthritis (OA) results in the progressive destruction of joint components, occurring from normal forces being applied on an abnormal joint, or abnormal forces acting on a normal joint (Kerwin, 2010; Moses, 2016). OA is common in older domestic cats but can be difficult to diagnose because of their stoic nature (Hellyer et al., 2007; AVMA, 2019; Stadig et al., 2019). Subtle changes in behaviour, a reduction in activity and a reluctance to jump are commonly observed, but lameness is often only present during flare-ups (Guillot et al., 2013). Non-steroidal anti-inflammatory drugs (NSAIDs) are the foundation for the management of these cases but adjunctive therapy with non-pharmaceuticals is beneficial. OA is also prevalent in captive felids, with stifle and elbow joints most affected in ageing individuals (Lascelles, 2010; Longley, 2011; Krebs et al., 2018).

The African serval (*Leptailurus serval*) is a small to medium-sized wild cat that is native to African grasslands. The species is considered of Least Concern on the IUCN Red List (Thiel, 2019) and has a lifespan of 23 years (Lamberski, 2015).

## Signalment and history

At less than 1 year old, and having already undergone an onychectomy on all four paws, the female African serval was confiscated from the pet trade as a customs seizure. In 2015, at approximately 6 years old, it arrived at ZSL from another zoological collection. The following year, the animal presented with left thoracic limb lameness. An oblique diaphyseal fracture of digit 4 P1 was diagnosed from radiographs. It is hypothesised that the onychectomy may have predisposed the serval to digit fractures because of the alteration of shock absorption and posture in locomotion and high-impact activities.

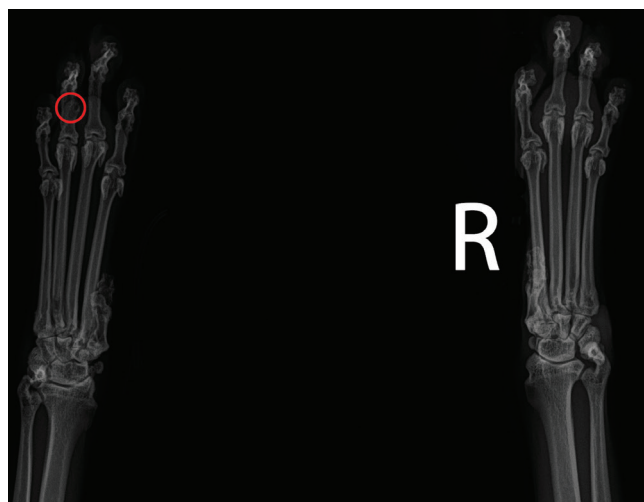
Pain management with the NSAID meloxicam (Metacam®, Boehringer Ingelheim), 0.15 mg/kg orally once daily, alongside restricted exercise and enclosure

modification, allowed the fracture to heal. A daily joint supplement, glucosamine and green-lipped mussel (300 mg glucosamine; 200 mg ActiveEase® green-lipped mussel (*Perna canaliculus*); 1.5 mg hyaluronic acid, YuMOVE Cat®, Lintbells) was also prescribed for long-term use. No further musculoskeletal abnormalities were detected until 2019, when the onset of clinical signs associated with OA were identified.

## Work-up, diagnosis and treatment

The serval presented with mild acute lameness in the right thoracic limb, which was worse in the mornings and more noticeable on uneven surfaces (bark chips). A course of meloxicam (Metacam®, Boehringer Ingelheim), 0.05 mg/kg orally once daily, was prescribed and the lameness resolved. However, when the NSAID course ended there was noticeable deterioration in the animal's gait, with keeping staff reporting intermittent hesitancy on the descent of ramps, slowness to rise and muscle weakness in the pelvic limbs.

A full health check under general anaesthesia (including radiographs) revealed osteophytes in the stifles bilaterally, the healed toe fracture, an irregular moth-eaten appearance to the distal aspects of the P2 bones of the thoracic limbs (**Figure 1**), bilateral stifle crepitus and muscle atrophy of the pelvic limbs. The P2 bones of the pelvic limbs also showed mild radiographic changes but not as significant as the thoracic limbs.



**Figure 1.** Thoracic limb radiographs showing bony changes to distal phalanx 2 (P2), and healed fracture of left D4, P1 (circled).

Long-term courses of pain relief medication were prescribed: daily oral meloxicam (Metacam®, Boehringer Ingelheim), 0.05 mg/kg increased to 0.15 mg/kg for short periods of acute lameness, and twice-daily oral gabapentin (Gabapentin oral solution, Rosemont® Pharmaceuticals Ltd), with doses adjusted to the clinical response, between 5 and 15 mg/kg, to target the neuropathic component associated with chronic pain (Grubb, 2018).

A healthcare plan was created, which included regular medication reviews, a biannual health examination, weekly gait analysis, photobiomodulation therapy (PBMT), exercise management and enclosure modifications. Health checks at 6-month intervals showed mild progression and subtle areas of lysis at P2 in the thoracic limbs, as well as an increase in joint space bilaterally in the stifles, indicating a loss of cartilage. Intermittent lameness was present with abduction of the right pelvic limb on the swing phase and a shortened stride length. Amantadine (Amantadine Hydrochloride, Morningside Healthcare) was added to the multimodal pain management plan, at a dose of 5 mg/kg orally once daily, to target the central sensitisation component of chronic pain (Grubb, 2018).

## Photobiomodulation therapy


PBMT uses wavelengths of light, which have biostimulatory effects on target tissues. The therapeutic benefits of PBMT include anti-inflammatory and analgesic effects, so its use is recommended in chronic pain management (Dadone & Harrison, 2017; Paterniani & Grolli, 2017). A Class 3b XP mobile unit (Omega Laser Systems) was used in the treatment of this case. Appropriate positioning and acceptance of the treatment was achieved through positive reinforcement and operant conditioning (learning that occurs when behaviour is affected by consequences) (Crowell-Davis, 2008). The serval was conditioned to lie in sternal recumbency on an elevated board. Shaping by successive approximations modified the position until the thoracic limbs could be extended rostrally and the time the position could be held allowed for treatment (**Figure 2**).

Treatment time varied depending on the animal's participation but averaged 4 min per session. A  $5 \times 820$  nm probe was used with  $16 \text{ J/cm}^2$  and a 1K frequency. The  $5 \times 820$  nm probe enabled treatment of larger areas in the same amount of time. The treatment was initially repeated for 3 consecutive days, then reduced to every 4 days and, at 8 weeks, reduced to once a week. Once maintenance treatment was established, the energy density and frequency were alternated to include  $24 \text{ J/cm}^2$  and 5K. Treatment of the stifles was also attempted but was not well tolerated.

In April 2020, all PBMT ceased, in line with a reduced contact policy with felids because of the Covid-19 risk. The animal was closely monitored and treatment was restarted a month later due to deterioration in gait coinciding with the serval sustaining an injury.

## Gait analysis

The assessment of gait, particularly identifying lameness in felids, is difficult and can be time-consuming (Schnabl-Feichter et al., 2020). However, pain associated with joint disease results in altered or impaired



**Figure 2.** Photobiomodulation treatment of digits in a 10-year-old female African serval with osteoarthritis secondary to onychectomy.

mobility, so it is an important part of assessment. A systematic and sequential approach to gait analysis was implemented and repeated for comparison. Videos were reviewed by the same veterinary nurse, for consistency, and seven gait criteria were assessed (**Table 1**).

The monitoring interval reduced over time, from monthly to weekly videos, as the disease progressed. These were obtained by the animal keepers and included an identical path of movement across an elevated walkway each morning. A turn both ways was included to assess feet placement, flexibility and balance. While videos from other aspects (front and rear views) would have given more information, only side-aspect videos were possible to obtain.

A simple scoring system was used to detect abnormalities: a score of one indicated the criteria assessed was normal, while a score of zero indicated an abnormality. This system did not allow for subjective grading of movement on a scale. Instead, it produced an overall numerical score, which was compared over time. High scores indicated a normal gait and good disease management.

## Enclosure modifications

Access to height is generally considered important for felids. A more complex environment including multiple levels encourages more movement, which is important for maintaining muscle mass and tone (Robertson & Lascelles, 2010).

**Table 1.** Criteria used for the assessment of the serval's gait via video recordings as part of regular monitoring.

Criteria	Assessment description	
	1 (Normal)	0 (Abnormal)
<b>Participation</b>	Willingly participates in movement with no hesitation.	Animal hesitates for 5 seconds or more before starting movement.
<b>Limb arc of flight</b>	Even and as expected limb protraction and retraction. Even hock and carpus lift and no evidence of paw rotation.	Reduced protraction or retraction of a limb, uneven height of hock or carpus. Visible rotation (pronation/supination) of foot.
<b>Stride</b>	Distance between one ground mark and the next made by the same paw is even. Normal stride length.	Distance between one ground mark and the next made by the same paw is uneven. Shorter or longer stride length.
<b>Stationary weight bearing</b>	All feet resting on the ground squarely with even distribution of weight. No toe touching or weight shifting.	One limb held off floor, or toe touching, or limb visibly trembles/shakes when weight bearing, weight shifting or uneven stance.
<b>Locomotive weight bearing</b>	While moving, all feet touch ground with full weight bearing. Stance phase of movement is even.	Uneven distribution of weight in stance phase. May only touch toe to floor, not flat of foot.
<b>Posture (head, neck and pelvis)</b>	Head carriage normal. Shoulders and pelvis level, spring through the back present (flexion/extension), movement is free, not stiff or jolted.	Head bobbing, neck extended or head carried low. Uneven level to shoulders and pelvis, tucked or crouched posture, stiff movement and minimal/no spring through the back.
<b>Turning</b>	Inside limb takes small stride, outside limbs take longer strides. Turn is a smooth movement. Limbs parallel, no abduction.	Visible wobble or imbalance, hop or other jerky movement. Hesitation for at least 5 seconds before performing turn.

Enclosure modifications were made to enable the serval to access all areas of the enclosure without jumping. Because of the animal's lack of claws, ramps were covered in Astroturf to provide grip. The addition of wooden 'steps' also eased navigation, particularly on descent. The bed area was elevated and provided a warm, draught-free look-out area – the serval spent an increasing amount of time here as the disease progressed, particularly on cold mornings.

### Exercise and activity levels

The serval was retired from public demonstrations in August 2019 but continued daily walks and exercise. This encouraged mobility and enabled keepers to assess its activity levels, gait and general demeanour. A reduction in daily activity is a common clinical sign in domestic cats with OA (Guillot et al., 2013) and this was reflected in this case. As the disease progressed, the serval became less engaged with enrichment items and hesitant to exercise.

A rapid assessment of the serval's activity levels and engagement with keepers enabled the tracking of behaviours over time. A tick-sheet describing activity level (active or stationary), enclosure usage (levels and ramps accessed), movement (any stiffness or lameness detected), engagement with enrichment and willingness to participate in training was completed five times per day (Table 2, overleaf). Exercise and diet modification helped to manage body weight, a key factor in the management of OA, as obesity increases pressure on joints and is likely to worsen OA and pain.

### Disease progression and end-of-life care

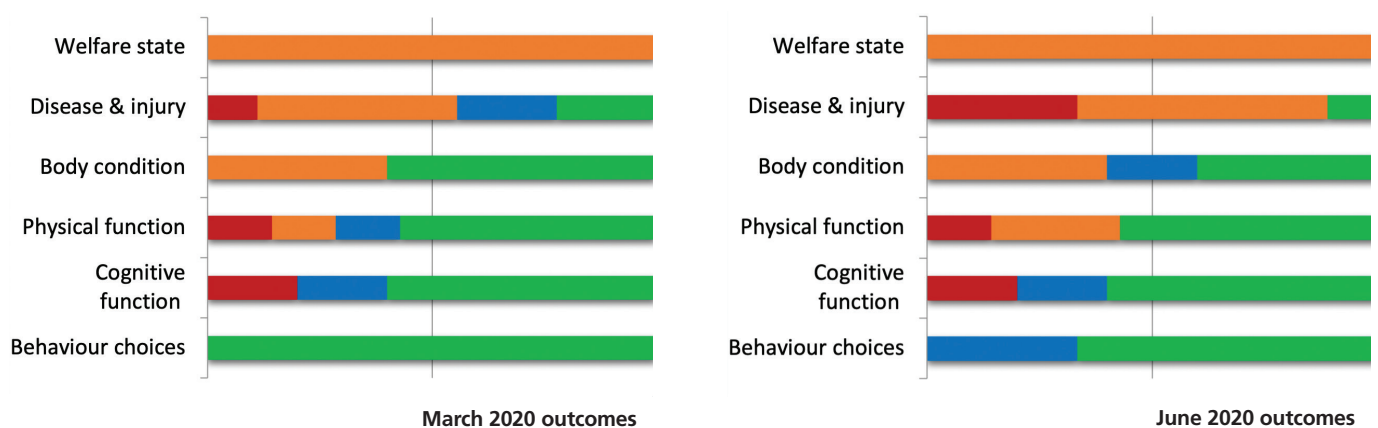
In May 2020, 15 months after the initial diagnosis, the animal deteriorated, following an episode of pacing and a suspected fall. There was increased bilateral laxity in the carpi when walking, with intermittent buckling of the left carpus. An increased amount of time was spent lying down and the animal's hair appeared unkempt,

**Table 2.** Record sheet completed by keepers for assessment of the serval's activity, enclosure usage and engagement.

	Date: 01/06/2020	Before medications	11 am	On lawn	2 pm	Lock up
<b>Mark all that apply</b>	Lying down, stationary in bed	X				X
	Moving all limbs, tracking normally			X	X	X
	Moving stiffly on one or more limbs	X				
	Moving with limp on one or more limbs		X			
	Pacing					
	Climbing up/down ramp					X
	Jumping				X	
<b>Enrichment/activity</b>	Engaged	X	X	X	X	X
	Did not engage					
	How long to go in box?			2 min		
	NA none offered					
<b>Notes</b>	e.g. which limb stiff, what activity affected	Slow to get up, mild lameness left fore	PBMT session with VN			Food enrichment

likely caused by a decrease in grooming. This is common in OA cases, secondary to pain and reduced flexibility (Moses, 2016). Pharmacological treatments had been titrated to meet the patient's needs, which is often required in disease processes associated with pain (Robertson & Lascelles, 2010). All medications were at the maximum dose, with clinical signs still present, indicating end-stage disease.

Repeated quality of life (QOL) assessments during illness and disease are critical in determining how the disease impacts the total wellbeing of the individual and the effectiveness of the care plan (Hellyer et al., 2007; Robertson & Lascelles, 2010). These assessments were carried out at frequent intervals because of the degenerative condition. The comparison of QOL outcomes in March 2020 and June 2020 identified a



**Figure 3.** March 2020 and June 2020 quality of life outcomes for a 10-year-old African serval with progressive OA, completed by animal husbandry staff, the veterinary team and the animal welfare officer with the use of supplementary monitoring tools (activity level observations, gait analysis and enclosure usage). Scale: affecting QOL to not affecting QOL – red, orange, blue, green, respectively.

deterioration in disease and injury, physical function and behavioural choice (**Figure 3**). This was echoed in the clinical signs and behavioural changes observed, resulting in a euthanasia decision. Trained behaviour was used to facilitate hand injection to induce general anaesthesia prior to euthanasia, resulting in a calm and welfare-positive euthanasia for this animal.

## Discussion

Age contributes to OA due to its degenerative nature but, in this case, the changes observed were likely to be secondary to the onychectomy, as the serval was not considered aged. Radiographs of a similar-aged female serval that had not undergone an onychectomy were examined retrospectively. These did not show any similarities: there were no bony changes in the digits and no radiographic evidence of OA in the stifles, further supporting this hypothesis.

Long-term complications of onychectomy in domestic cats include claw regrowth, lameness, chronic pain, palmigrade stance and flexor tendon contraction, but there is a lack of conclusive data (Clark et al., 2014; Ruch-Gaille, 2016; Martell-Moran et al., 2018). Long-term lameness is often difficult to observe as cats are commonly bilaterally lame on the thoracic limbs and lameness is considered secondary to chronic pain. However, the effects as a direct result of an onychectomy are not well described (Martell-Moran et al., 2018). P3 is important in the digitigrade stance of felids, so a functional change in gait to accommodate in onychectomised felids should also be considered (Clark et al., 2014). The ability to engage in hardwired species-specific behaviours like scratching and climbing is eliminated by an onychectomy, which may lead to chronic stress in domestic felids (Kogan et al., 2016; Ruch-Gaille et al., 2016).

Servals are larger and heavier than domestic cats and are known for their ability to jump. This could have increased the risk of OA secondary to onychectomy, with additional weight and force carried through the joints alongside a reduction in shock absorption. OA changes on radiographs were significantly worse in the thoracic limbs, which was likely to be due to the natural weight distribution and position of the centre of gravity. Thoracic limbs carry 60% of body weight, as well as being the primary contact and shock absorber for the percussive force of landing (Beaver, 2003). Little is known about the serval's history prior to confiscation from the pet trade, its age at the time of onychectomy and the method used, which could also have affected the development of OA.

Monitoring with regular radiographs allowed clinical assessment of disease progression. A multimodal approach to analgesia targeted the specific components of chronic and maladaptive pain associated with OA. Alongside medical management, PBMT was

included within the treatment plan, as a non-invasive, complementary therapy that is widely used in species across ZSL (Sparrow, 2020). The holistic approach to this case encompassed both the health and welfare of the individual. The use of assessment tools, such as gait analysis and QOL, provided the feedback needed to create a unique and adaptive treatment plan that focused on the individual.

## Acknowledgements

The author would like to thank the ZSL Wildlife Health Services team and the animal keeper team.

## REFERENCES (CONTINUES OVERLEAF)

- American Veterinary Medical Association (2019) Literature Review: Welfare implications of declawing of domestic cats. Available from: <https://www.avma.org/resources-tools/literature-reviews/welfare-implications-declawing-domestic-cats> [Accessed 31 May 2021]
- Animal Welfare Act (2006) Section 5. Available from: <https://www.legislation.gov.uk/ukpga/2006/45/section/5> [Accessed 31 May 2021]
- Beaver, B. V. (2003) *Feline Behaviour: A Guide for Veterinarians*. St. Louis, Elsevier Saunders.
- Clark, K., Bailey, T., Rist, P. & Matthews, A. (2014). Comparison of three methods of onychectomy. *Canadian Veterinary Journal*. 55 (3), 255–262. Available from: <https://www.ncbi.nlm.nih.gov/pmc/articles/PMC3923482/> [Accessed 10 October 2020]
- Crowell-Davis, S. L. (2008) Use of operant conditioning to facilitate examination of zoo animals. *Compendium*. 30 (4) 218–236. Available from: [http://assets.prod.vetlearn.com.s3.amazonaws.com/mmah/22/6c062095f14afeaaf041deaade802b/filePV\\_30\\_04\\_218.pdf](http://assets.prod.vetlearn.com.s3.amazonaws.com/mmah/22/6c062095f14afeaaf041deaade802b/filePV_30_04_218.pdf) [Accessed 26 July 2021]
- Dadone, L. & Harrison, T. (2017) Zoological applications of laser therapy. In: Riegel R. J. & Godbold J. C. (eds.) *Laser Therapy in Veterinary Medicine: Photobiomodulation*. 1st ed. Ames, John Wiley & Sons, pp. 320–334.
- Grubb, T. (2018) Gabapentin and amantadine for chronic pain: Is your dose right? *Today's Veterinary Practice*. Available from: <https://todaysveterinarypractice.com/gabapentin-and-amantadine-for-chronic-pain/> [Accessed 26 October 2020].
- Guillot, M., Moreau, M., Heit, M., Martel-Pelletier, J., Pelletier, J.-P. & Troncy, E. (2013) Characterization of osteoarthritis in cats and meloxicam efficacy using objective chronic pain evaluation tools. *The Veterinary Journal*. 196 (3), 360–367. Available from: <https://doi.org/10.1016/j.tvjl.2013.01.009> [Accessed 4 September 2020].
- Hellyer, P., Rodan, I., Brunt, J., Downing, R., Hagedorn, E. J. & Robertson, S. A. (2007) AAHA/AAFP pain management guidelines for dogs and cats. *Journal of Feline Medicine and Surgery*. 9 (6), 466–480. Available from: <https://doi.org/10.1016/j.jfms.2007.09.001>
- Kerwin, S. C. (2010) Osteoarthritis in cats. *Topics Companion Animal Medicine*, 25 (4) 218–223. Available from: <https://doi.org/10.1053/j.tcam.2010.09.004> [Accessed 10 October 2020]
- Kogan, L. R., Little, S. E., Hellyer, P. W., Schoenfeld-Tacher, R. & Ruch-Gaille, R. (2016) Feline onychectomy: current practices and perceptions of veterinarians in Ontario, Canada. *Canadian Veterinary Journal*. 57 (9), 969–975. Available from: <https://www.ncbi.nlm.nih.gov/pmc/articles/PMC4982569/> [Accessed 14 April 2021]
- Krebs, B. L., Marrin, D., Phelps, A., Krol, L. & Watters, J. V. (2018) Managing aged animals in zoos to promote positive welfare: a review and future directions. *Animals*. 8 (7), 116. Available from: <https://doi.org/10.3390/ani8070116> [Accessed 31 May 2021]
- Lamberski, N. (2015) Felidae. In: Miller, E. R. & Fowler, M. E. (eds.) *Fowler's Zoo and Wild Animal Medicine*, Volume 8. St. Louis, Elsevier Saunders, pp. 467–476.
- Lascelles, B. D. (2010) Feline degenerative joint disease. *Veterinary Surgery*. 39 (1), 2–13. Available from: <https://doi.org/10.1111/j.1532-950X.2009.00597.x>

## REFERENCES (CONTINUED)

- Longley, L. (2011) A review of ageing studies in captive felids. *International Zoo Yearbook*. 45 (1), 91–98. Available from: <https://doi.org/10.1111/j.1748-1090.2010.00125.x> [Accessed 31 May 2021].
- Martell-Moran, N, K., Solano, M., & Townsend, H, G. (2018) Pain and adverse behaviour in declawed cats. *Journal of Feline Medicine and Surgery*. 20 (4), 280–288. Available from: <https://doi.org/10.1177/1098612X17705044> [Accessed 26 October 2020].
- Moses, P, A. (2016) Feline Osteoarthritis. NAVC Conference Proceedings 2016, Orlando, Florida, USA.
- Paterniani V, Grolli S. (2017) Approach and potentiality of low level laser therapy in veterinary medicine. Paper presented at: Laser Florence. Proceedings volume 10582 of Laser Florence, Florence, Italy.
- Robertson, S. & Lascelles, D. (2010) Long-term pain in cats: how much do we know about this important welfare issue? *Journal of Feline Medicine and Surgery*. 12 (3), 188–199. Available from: <https://doi.org/10.1016/j.jfms.2010.01.002> [Accessed 10 October 2020]
- Ruch-Gallie, R., Hellyer, P. W., Schoenfeld-Tacher, R. & Kogan, L, R. (2016) Survey of practices and perceptions regarding feline onychectomy among private practitioners. *Journal of the American Veterinary Medical Association*. 249 (3), 291–298. Available from: <https://doi.org/10.2460/javma.249.3.291> [Accessed 24 September 2020]
- Schnabl-Feichter, E., Tichy, A., & Bockstahler, B. (2020) Evaluation of a pressure plate for detection of hind limb lameness in cats. *PLOS One*. 15 (4), e0231904. Available from: <https://doi.org/10.1371/journal.pone.0231904> [Accessed 26 October 2020]
- Sparrow, S. J. (2020) Clinical application of photobiomodulation therapy in a zoological setting. *The Veterinary Nurse*. 11 (10), 460–464. Available from: <https://www.theveterinarynurse.com/review/article/clinical-application-of-photobiomodulation-therapy-in-a-zoological-setting> [Accessed 8 August 2022]
- Stadig, S., Lascelles, B, D., Nyman, G. & Bergh, A. (2019) Evaluation and comparison of pain questionnaires for clinical screening of osteoarthritis in cats. *Veterinary Record*. 185 (24), 757. Available from: <https://doi.org/10.1136/vr.105115>
- Thiel, C. (2019) *Leptailurus serval* (amended version of 2015 assessment). The IUCN Red List of Threatened Species 2019. Available from: <https://dx.doi.org/10.2305/IUCN.UK.2019-3.RLTS.T11638A156536762.en> [Accessed 16 May 2021]

Reflective professional development notes. To access hyperlinks to the references, scan the QR code on page 3.