

# Bilateral ureteral obstruction and subcutaneous ureteral bypasses: a feline case report

Part 2 DOI 10.1080/17415349.2021.1944415

Chelsey Surgenor | RVN BSc (Hons) | Pride Veterinary Centre, Derbyshire, UK

**ABSTRACT** Bilateral ureteral obstruction in felines is relatively uncommon, with subsequent placement of bilateral subcutaneous ureteral bypasses even more uncommon for veterinary nurses to encounter in practice. This case report covers the presentation, diagnostics, treatment, nursing care, complications and ongoing outpatient care of Kolo, a two-year-old ragdoll, who presented with this condition and ultimately required surgical intervention for a successful outcome. Part 2 encompasses the patient's journey following discharge, including oesophagostomy feeding tube demonstration and home care, repeat blood tests, life-long SUB™ flush procedures, dietary considerations, complications and management. A glossary of terms can be found at the end of Part 1.

**Key words** outpatient; renal; feline medicine; oesophagostomy; nursing care; case study

## Introduction

Part 1 introduced the case report of Kolo, a two-year-old female neutered ragdoll who presented with bilateral ureteral stones and severe azotaemia. Surgical intervention of bilateral subcutaneous ureteral bypass (SUB™) placement was performed and the patient's azotaemia resolved. Part 2 focuses on the outpatient care of Kolo from discharge and the life-long monitoring and maintenance required.

## Subcutaneous ureteral bypass: a recap

A single SUB™ system consists of three key components: a nephrostomy catheter, a SwirlPort™,

and a cystostomy catheter (Norfolk Vet Products, 2018a). Part 1 of the case report includes an image of a SUB™ device prior to surgical placement. Figure 1 consists of an illustrative diagram of a SUB™ device in situ. Fundamentally, these combine as one permanent fixture to function as an artificial indwelling ureter. Without complications, the patient's urinary system can continue to function as normal without assistance. However, a form of maintenance is required throughout the rest of the patient's life, which will be discussed in this article.

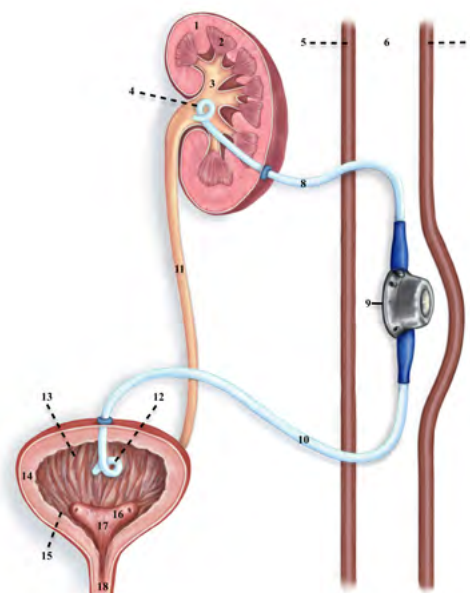


Figure 1. Educational illustration by, and courtesy of, Kirsty Kinneard ([www.kirstykinneardart.com](http://www.kirstykinneardart.com)). 1. Renal cortex, 2. Renal medulla, 3. Renal pelvis, 4. Pigtail tip, 5. Abdominal wall, 6. Subcutaneous space, 7. Skin, 8. Nephrostomy catheter, 9. Swirlport™, 10. Cystostomy catheter, 11. Ureter, 12. Pigtail tip, 13. Urinary bladder apex, 14. Detrusor muscle, 15. Mucosa/Rugae, 16. Ureter orifices, 17. Trigone, 18. Urethra.

## Discharge and outpatient care

### LONG-TERM OUTPATIENT CARE: BLOODS AND SUB™ FLUSH PROCEDURES

Ongoing monitoring of renal values and maintenance of the SUB™s is critical to the patient's long-term survival and quality of life.

Maintenance of the SUB™s is achieved via a flushing procedure of the SUB™ device. The patient required sedation, was positioned in dorsal recumbency and an ultrasound was performed. The renal pelvis was measured and recorded prior to flushing. The SwirlPort™s were palpable beneath the skin. The hair was clipped and prepped aseptically to the same standard as surgery requirements, with consideration that the SwirlPort™s were the core sites of entry. Norfolk Vet Products provide a sterile flush kit specifically to perform the SUB™ flush procedure, all items of which consist of a luer lock system (Figure 2).

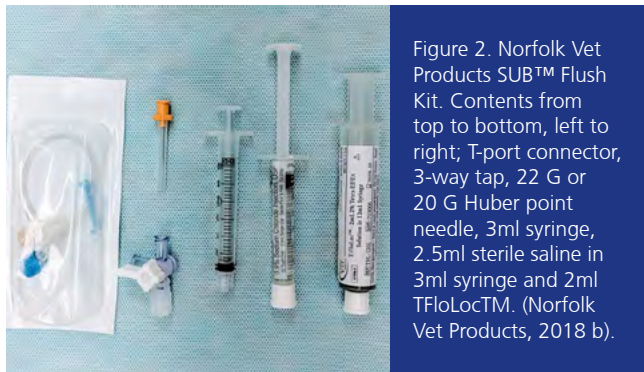


Figure 2. Norfolk Vet Products SUB™ Flush Kit. Contents from top to bottom, left to right; T-port connector, 3-way tap, 22 G or 20 G Huber point needle, 3ml syringe, 2.5ml sterile saline in 3ml syringe and 2ml TFloLoc™. (Norfolk Vet Products, 2018 b).

The veterinary surgeon performing the procedure open gloved with an aseptic technique and unpacked the flush kit onto a sterile drape. The following is attached in order: Huber point needle to the T-port connector and then to the 3-way tap. The 3ml syringe and sterile saline syringe are each attached to the 3-way tap.

The silicone insertion site within the SwirlPort™ was palpated and the Huber point needle was advanced perpendicularly through the skin and silicone until resistance felt when metal reached (Figures 3 and 4). The 3ml syringe was then drawn back to obtain a urine sample for urinalysis, culture and sensitivity.

The ultrasound then located the renal pelvis. The 3-way tap was twisted to occlude the urine sample syringe and enable the sterile saline to be flushed through. The presence of small bubbles in the renal pelvis confirmed that the saline had entered, thereby confirming appropriate placement and patency of the nephrostomy catheter. The saline was then drawn back into the same syringe. The ultrasound then located the bladder, and the saline was flushed again. Bubbles were present in the bladder, confirming saline entering and therefore appropriate placement and patency of the cystostomy catheter.

With patency confirmed, the urine sample syringe was removed from the 3-way tap and the T-FloLoc™ syringe was attached. T-FloLoc™ contains a 2% tetrasodium ethylenediaminetetraacetic (tetra-EDTA) solution. The 3-way tap was twisted to occlude the saline syringe, and enable the T-FloLoc™ syringe to be flushed slowly in pulses, while the ultrasound monitored the renal pelvis for overdistension. The T-FloLoc™ solution is not drawn back, but remains in the device for the purpose of maintaining patency and infection control (Table 1) (Norfolk Vet Products, 2018b). Once completed, the process was repeated on the other side with a new sterile flush kit.

It is worth noting that the SwirlPort™ was allocated to the diagonal kidney, for example the left SwirlPort™ was connected to the right kidney, and that this technique of flushing is for prophylactic purposes only. Findings have also demonstrated that 2% tetra-EDTA infusions can resolve mineral occlusions of SUB™ devices, preventing the need to replace the system (Chik et al., 2019).

In this case, the frequency of SUB™ flushing was performed at five days and 20 days following placement. No complications were reported during these procedures, and therefore the next procedure will be performed at three months if no complications arise in the meantime. Thereafter, the frequency of SUB™ flushing will reduce to every three to six months, depending on the patient.

Blood tests will be repeated, depending on the progression or deterioration of the patient. They will be repeated at each SUB™ flush procedure, increasing frequency if indicated.

### OE SOPHAGOSTOMY TUBE SUPPORT

Due to the patient's ongoing inappetence but improving renal parameters, it was opted to discharge with the oesophagostomy tube in place. Upon discharge, a nurse discussed and demonstrated how to administer tube feeds, maintain the tube and perform dressing changes. A 'feeding-kit' box was given to the owner with all the necessary consumables to complete these tasks.

To aid clear communication, the box also included written step-by-step instructions and a feeding chart to help the owner monitor the patient's intake. Furthermore, the practice had a pre-recorded video of the demonstrations which was emailed to the owner, while ongoing phone communications with both vets and nurses were frequent. This enabled multiple forms of communication to be available and allowed the owner to reflect and recap following discharge, with means of communication to resolve any issues or queries post-discharge. Overall, the combined methods of communication were considered thorough and successful in supporting the client and outcome for the patient.

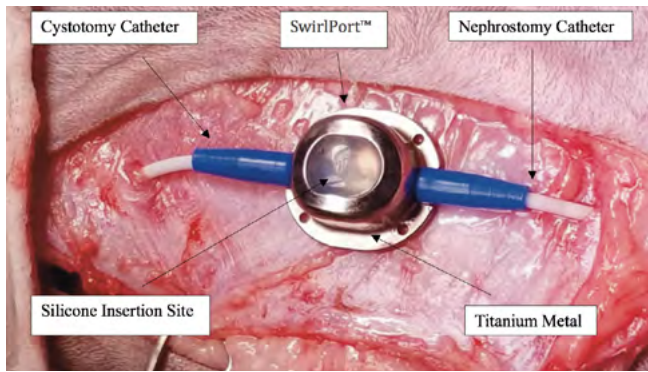


Figure 3. Labeled photograph of SwirlPort™ placed subcutaneously. Adapted from (Norfolk Vet Products, 2018c).

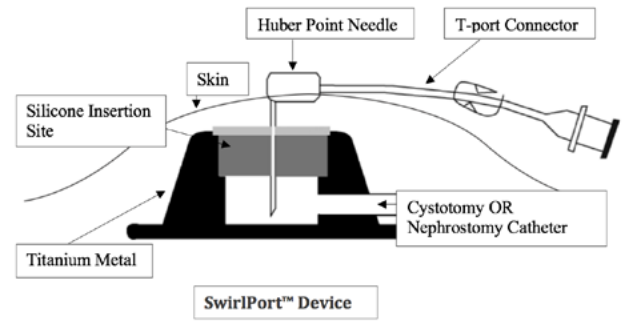


Figure 4. Diagram of a SwirlPort™ and Huber point needle during a SUB™ flush procedure. Adapted from (Norfolk Vet Products, 2018c).

Table 1. Actions of T-FloLoc™ (2% tetra-EDTA) flush and lock solution (Norfolk Vet Products, 2018b).

Mechanism	Action
Broad spectrum activity	Effective against both gram-positive and gram-negative bacteria.
Prevents and eliminates biofilm	Reduces microbial colonisation.
Effective anticoagulant	Aids and sustains patency while avoiding systemic anticoagulation.
Non-toxic	No known topical or systemic effects.
Anti-resistance	Does not induce drug resistant bacteria.
Reduces mineralisation	Aids prevention of occlusion from mineralisation.

Once home, the owner reported that the patient gradually increased consumption of food and the tube feeds were able to be reduced accordingly. Once self-sustaining well without supportive feeds, the oesophagostomy tube was removed. The removal was performed as a nurse consult and the stoma site healed quickly via secondary intention healing. No oesophagostomy-tube-associated complications were reported.

### LONG-TERM DIET

With the likelihood that the case was obstructed due to calcium oxalate ureteroliths, dietary management may be considered relevant in prevention of recurrence. It must be noted that calcium oxalate stones and crystals cannot be dissolved. Factors involved in the pathogenesis of calcium oxalate ureterolithiasis and urolithiasis are poorly understood, but supersaturation of urine, hypercalcaemia and urine-acidifying diets are considered significant (Grauer, 2015; Kirk et al., 1995). As previously discussed, urinalysis is performed at each sub flush procedure which can allow for identification of crystalluria. In calcium oxalate cases, if urine specific gravity is >1.030 it is recommended to consider a wet food or encourage an increase in water intake through methods such as running water fountains, different bowls and locations.

If urine pH is <6.25 then a diet that promotes a reduction in urine acidity or adding urinary alkalisers

should be considered to minimise recurrence (Minnesota Urolith Center, 2021).

At the time of writing, the patient had not been placed on a urinary specific diet to reduce acidity, as overcoming inappetence and avoiding food aversion were of initial importance. A specific diet to prevent calcium oxalate formation can become a more predominant factor in management once the patient is considered more consistently stabilised. Furthermore, it should be considered in this case that both urinary oxalate and renal considerations are significant and, as such, both components should be encompassed for dietary recommendations.

### COMPLICATIONS

With a significance of hypercalcaemia in the formation of calcium oxalates found, plus significant association found between high post-operative ionised calcium concentration and SUB™ device occlusion, calcium parameters should be monitored (Berent et al., 2018). There is a high level of diagnostic discordance between total calcium and ionised calcium. Many cats presented as normocalcaemic when measuring total calcium, but ionised calcium indicated derangement of calcium homeostasis (Schenck & Chew, 2010). It has therefore been advised to measure ionised calcium in calcium oxalate cases. In the patient discussed, ionised calcium proved to be intermittently elevated initially, but appears to have stabilised post-discharge (Table 2 of Part 1).

Persistent mild cystitis was a complication presented in this case, with the clinical signs of pollakuria and dysuria being prominent. Cystitis is often associated with feline lower urinary tract disease (FLUTD) and is most commonly idiopathic. Although the aetiology of cystitis is not well understood, stress has a strong association. In this case both the SUB™ placement and stress may have been likely contributors. Kulendra et al. (2021) suggested that cats demonstrating dysuria following SUB™ placement may be due to the cystotomy catheter(s) being placed close to and within the bladder apex, potentially causing irritation, inflammation and subsequent cystitis. The degree of irritation and inflammation should be limited however, due to the pigtail tip design that was a specific modification in response to one reported case of an ulcer in the mucosa of the bladder as a result of the cystotomy catheter tip. One study reported that 12.5% of cats with SUB™ placement experienced sterile cystitis (Vrijzen et al., 2020). Although a variety of randomised clinical trials have been performed, no drug therapy has been identified as effective in feline idiopathic cystitis (FIC) (Poole, 2020; Sparkes, 2018). Many studies and findings on feline cystitis primarily focus on idiopathic cases. However, with the SUB™ device being the primary cause of cystitis in this case, opposed to idiopathic, it is limiting to apply current published findings to the treatment of this case.

In response to the ongoing cystitis, the patient was started on prednisolone (2.5mg SID) and prazosin (0.5mg q8h), a urethral sphincter muscle relaxant. The owner reported improvement, although not full resolution, and was satisfied with the patient's quality of life.

Other complications reported in cats with SUB™ placement include device occlusion from clots and stones, urinary tract infections (UTI), device leakage and kinking, and irreversible kidney damage. However, in a study of 134 cats with SUB™ placement 94% survived to discharge, and in another study of 95 cats, 89.5% survived to discharge. Overall, most studies have found that SUB™ placement is associated with a high prevalence of complications but with a median survival time of more than two years, suggesting that the majority of complications were manageable as was observed in the discussed patient (Berent et al., 2018; Kulendra et al., 2021).

## Discussion

Cases of bilateral ureteral obstruction being resolved with bilateral subcutaneous ureteral bypass placement have proven to be relatively rare. The multidisciplinary approach and holistic nursing required

has been comprehensive but would not have been successful without the ongoing commitment and dedication of the owner.

Some may perceive the interventions and ongoing maintenance and monitoring to be considerably invasive, which could raise ethical concerns. However, as with any case, individual assessment is essential. What may be suitable for one case, may not be suitable for another. Both patient and owner should be considered individually. With medical management being unsuccessful, surgical intervention and euthanasia were the only viable options.

## Conclusion

Thus far, the patient has had minimal complications, with the owner reporting a good quality of life despite recurring cystitis which they have considered manageable. The commitment of the owner and temperament of the patient bodes well with the ongoing requirements following SUB™ placement. Overall, holistic involvement of multiple disciplines, nursing care, owner compliance and patient compatibility is key to a successful outcome.

## Acknowledgements

This article was enabled through the kind consent of Kolo's committed owner and the treating practice Pride Veterinary Centre. Gratitude to the primary clinicians overseeing Kolo's case: Jessica Adamany BSc DVM DipECVIM-CA MRCVS, Specialist of Internal Medicine who spent time proofreading this article and answering many questions, and Rosario Vallefucio DVM DipECVS MRCVS Specialist of Small Animal Surgery. Furthermore, the number of staff involved in Kolo's care from the beginning, whether directly or indirectly, is unquantifiable but to everyone at Pride: thank you.

## REFERENCES

- Berent, A. C., Weisse, C. W., Bagley, D. H., & Lamb, K. (2018). Use of a subcutaneous ureteral bypass device for treatment of benign ureteral obstruction in cats: 174 ureters in 134 cats (2009-2015). *Journal of the American Veterinary Medical Association*, 253(10), 1309–1327. <https://doi.org/10.2460/javma.253.10.1309>
- Chik, C., Berent, A. C., Weisse, C. W., & Ryder, M. (2019). Therapeutic use of tetrasodium ethylenediaminetetraacetic acid solution for treatment of subcutaneous ureteral bypass device mineralization in cats. *Journal of Veterinary Internal Medicine*, 33(5), 2124–2132. <https://doi.org/10.1111/jvim.15582>
- Grauer, G. F. (2015). Feline struvite and calcium oxalate urolithiasis. *Today's Veterinary Practice*. Online: <https://todaysveterinarypractice.com/wp-content/uploads/sites/4/2016/06/T1509F01.pdf>
- Kinneard, K. (2021). Educational illustration. <https://www.kirstykinneardart.com>
- Kirk, C. A., Ling, G. V., Franti, C. E., & Scarlett, J. M. (1995). Evaluation of factors associated with development of calcium oxalate urolithiasis in cats. *Journal of the American Veterinary Medical Association*, 207(11), 1429–1434.
- Kulendra, N. J., Borgeat, K., Syme, H., Dirrig, H., & Halfacree, Z. (2021). Survival and complications in cats treated with subcutaneous ureteral bypass. *Journal of Small Animal Practice*, 62(1), 4–11. <https://doi.org/10.1111/jsap.13226>
- Minnesota Urolith Center (2021). Feline calcium oxalate uroliths. Online: [https://vetmed.umn.edu/sites/vetmed.umn.edu/files/feline\\_calcium\\_oxalate\\_uroliths.pdf](https://vetmed.umn.edu/sites/vetmed.umn.edu/files/feline_calcium_oxalate_uroliths.pdf)
- Norfolk Vet Products (2018a). The improved therapeutic option for dogs and cats to bypass ureteral obstructions. Online: <https://norfolkvetproducts.com/products/sub-2/>
- Norfolk Vet Products (2018b). The premium catheter flushing and locking solution offering both patency and infection control. Online: <https://norfolkvetproducts.com/products/t-floloc/>
- Norfolk Vet Products (2018c). The SUB 2.0: A surgical guide. Online: [https://norfolkvetproducts.com/PDF/SUB/SUB2\\_Surgical\\_Guide\\_2018-03-email.pdf](https://norfolkvetproducts.com/PDF/SUB/SUB2_Surgical_Guide_2018-03-email.pdf)
- Poole, A. (2020). Feline idiopathic cystitis: What to suggest. *The Veterinary Nurse*, 11(4), 161–165. <https://doi.org/10.12968/vetn.2020.11.4.161>
- Schenck, P. A., & Chew, D. J. (2010). Prediction of serum ionised calcium concentration by serum total calcium measurements in cats. *Canadian Journal of Veterinary Research*, 73(4), 209–213.
- Sparkes, A. (2018). Understanding feline idiopathic cystitis. *In Practice*, 40(3), 95–101. <https://doi.org/10.1136/inp.k435>
- Vrijnsen, E., Devriendt, N., Mortier, F., Stock, E., Van Goethem, B and de Rooster, H. (2020). Complications and survival after subcutaneous ureteral bypass device placement in 24 cats: A retrospective study (2016-2019). *Journal of Feline Medicine and Surgery*. Online: <https://doi.org/10.1177/1098612X20975374>

Reflective professional development notes. To access hyperlinks to the references, scan the QR code on page 3.